

USMLE^{Q&As}

United States Medical Licensing Examination

Pass USMLE USMLE Exam with 100% Guarantee

Free Download Real Questions & Answers **PDF** and **VCE** file from:

<https://www.pass2lead.com/usmle.html>

100% Passing Guarantee
100% Money Back Assurance

Following Questions and Answers are all new published by USMLE
Official Exam Center

- ⚙️ **Instant Download** After Purchase
- ⚙️ **100% Money Back** Guarantee
- ⚙️ **365 Days** Free Update
- ⚙️ **800,000+** Satisfied Customers



QUESTION 1

Which of the following is not true about Type I DM?

- A. May be linked to autoimmunity
- B. Onset usually prior to age 20
- C. Beta islet cells destroyed
- D. Does not require insulin injections

Correct Answer: D

QUESTION 2

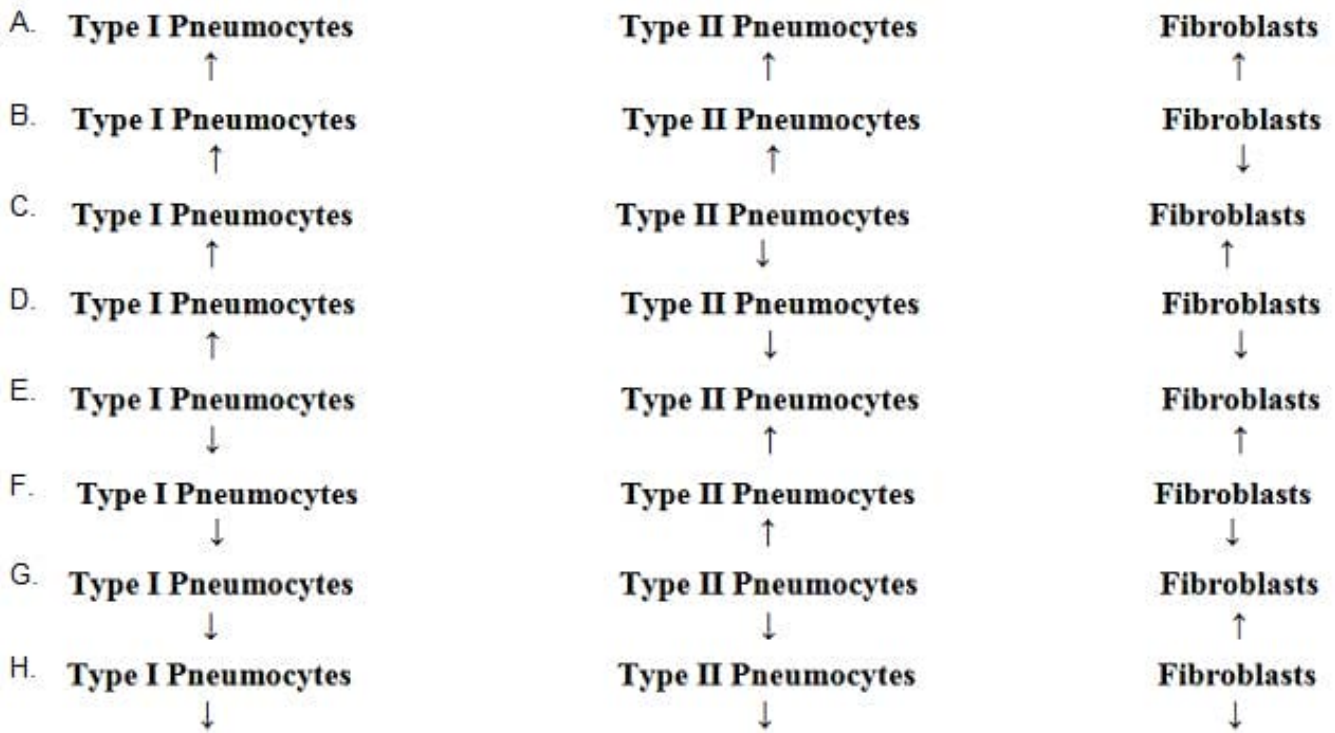
A 46-year-old woman with active ankylosing spondylitis comes to the office for a follow-up examination. The use of various conventional nonsteroidal anti-inflammatory drugs has been ineffective. Sulfasalazine treatment also has not resulted in improvement. The most appropriate next step in treatment is administration of a drug that inhibits which of the following?

- A. CD20
- B. Cyclooxygenase-2
- C. Cytotoxic T-lymphocyte antigen 4
- D. Epidermal growth factor
- E. Interleukin-1 (IL-1)
- F. Tumor necrosis factor ?

Correct Answer: F

QUESTION 3

A 62-year-old man comes to the physician for a follow-up examination after he was diagnosed with chronic inflammatory interstitial pneumonitis. Following pulmonary function testing, a biopsy specimen of the affected area of the lungs is obtained. Compared with a healthy man, analysis of this patient's biopsy specimen is most likely to show which of the following patterns of changes in the cell populations of alveoli?



- A. Option A
 - B. Option B
 - C. Option C
 - D. Option D
 - E. Option E
 - F. Option F
 - G. Option G
 - H. Option H
- Correct Answer: E

QUESTION 4

Which of the following is not true concerning Brown-Sequard syndrome?

- A. Contralateral spinothalamic deficits
- B. Ipsilateral spinothalamic deficits
- C. Ipsilateral dorsal column deficits

D. Ipsilateral pyramidal tract deficits

Correct Answer: B

QUESTION 5

A 27-year-old man is admitted to the hospital 45 minutes after being involved in a motor vehicle collision. Physical examination shows a sluggish response to stimuli. Neurologic examination shows no other abnormalities. A skull x-ray shows a linear, nondepressed basal skull fracture. Two weeks later, the patient develops polyuria and polydipsia. Laboratory studies show a serum glucose concentration within the reference range, increased serum osmolality, and decreased urine osmolality. Following the administration of desmopressin, urine osmolality increases. The beneficial effect of this drug is most likely due to activation of which of the following?

- A. Adenylyl cyclase
- B. Ca²⁺ channels
- C. Janus kinase
- D. Serine kinase
- E. Tyrosine kinase

Correct Answer: A